

FORENSIC ANTHROPOLOGY AND CRIMINAL INVESTIGATIONS

Donna C. Boyd, Ph. D., D-ABFA
Professor of Anthropological Sciences
Co-Director, RU Forensic Science
Institute, Radford University, VA

Forensic Anthropology



- ▣ What is Forensic Anthropology?
- ▣ What Kind of Training Does a Forensic Anthropologist Have?
- ▣ What are the Myths About Forensic Anthropology?
- ▣ What are the Goals of Forensic Anthropology?

Mass Fatality Incidents



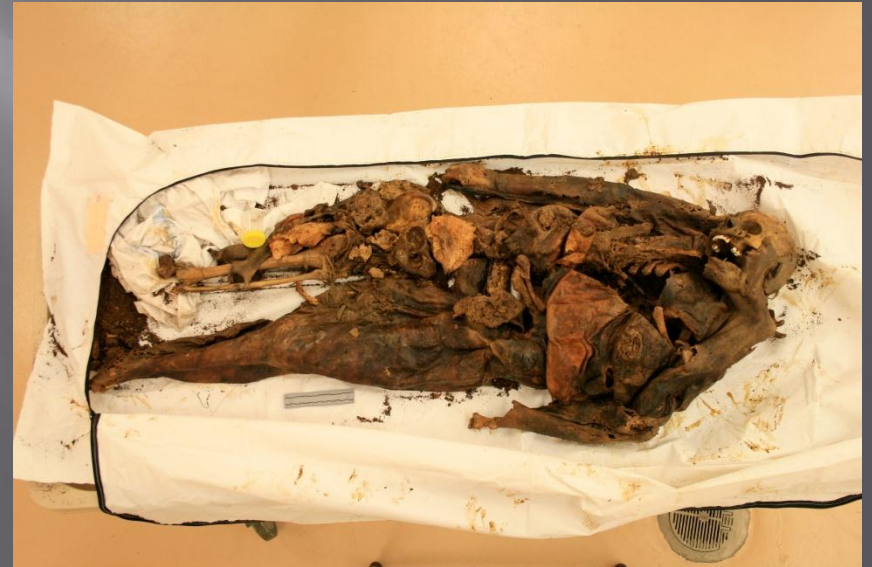Mass Disasters



Forensic Anthropological Stages of Investigation

- ▣ Field Reconnaissance
- ▣ Laboratory Curation and Analysis

Determination of Forensic Significance



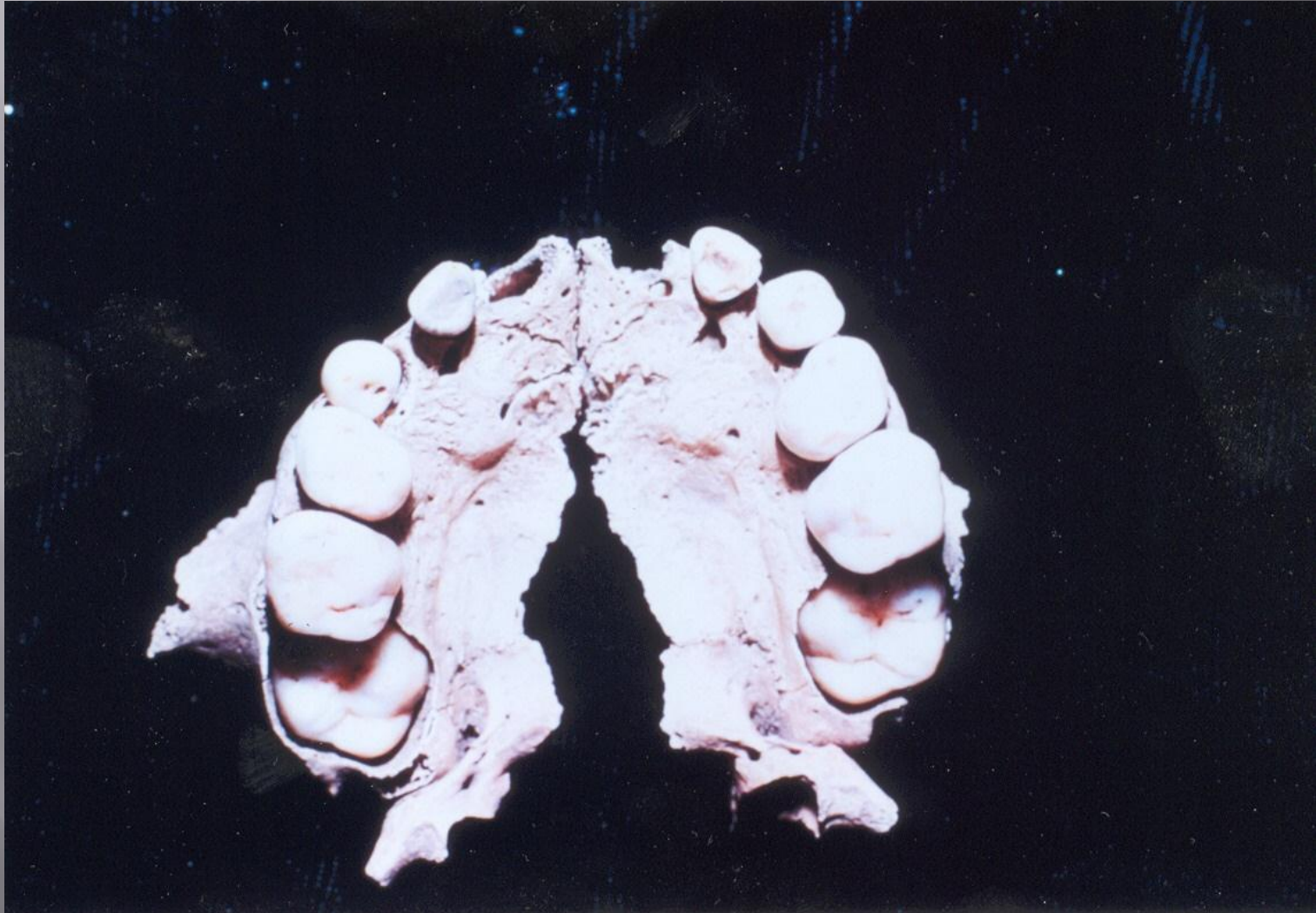
Processing



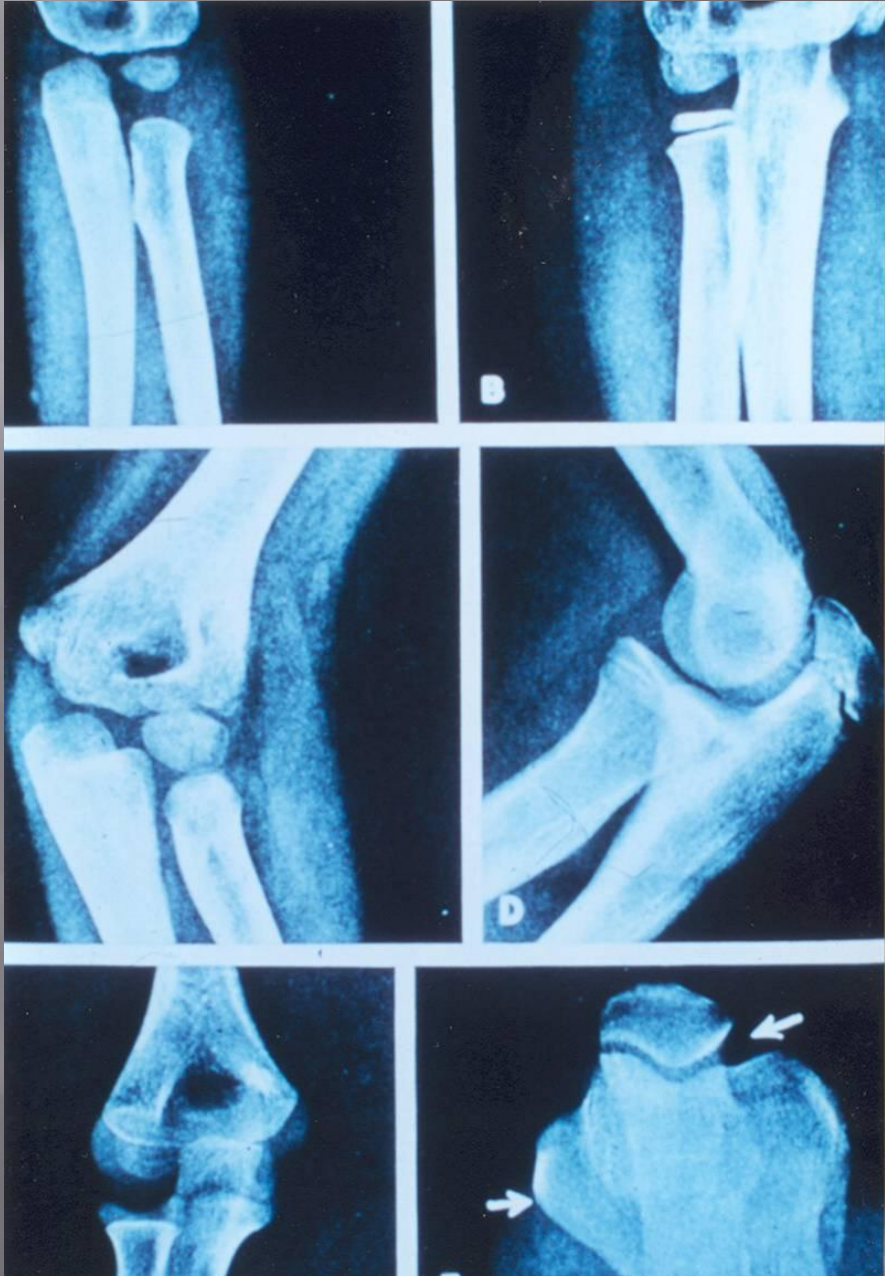
Bone Inventory and MNI

Biological Profile

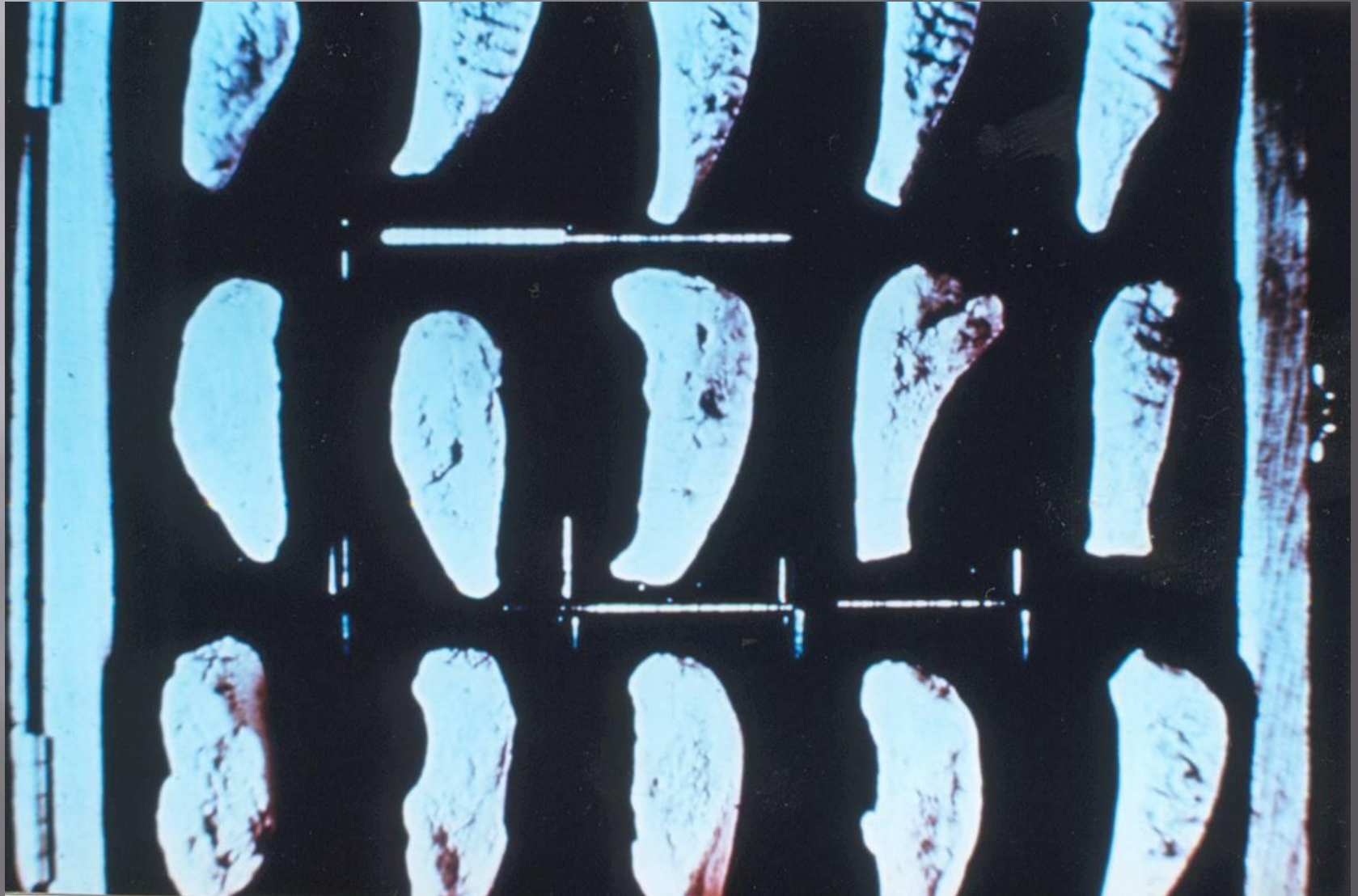
Subadult Age: Dental



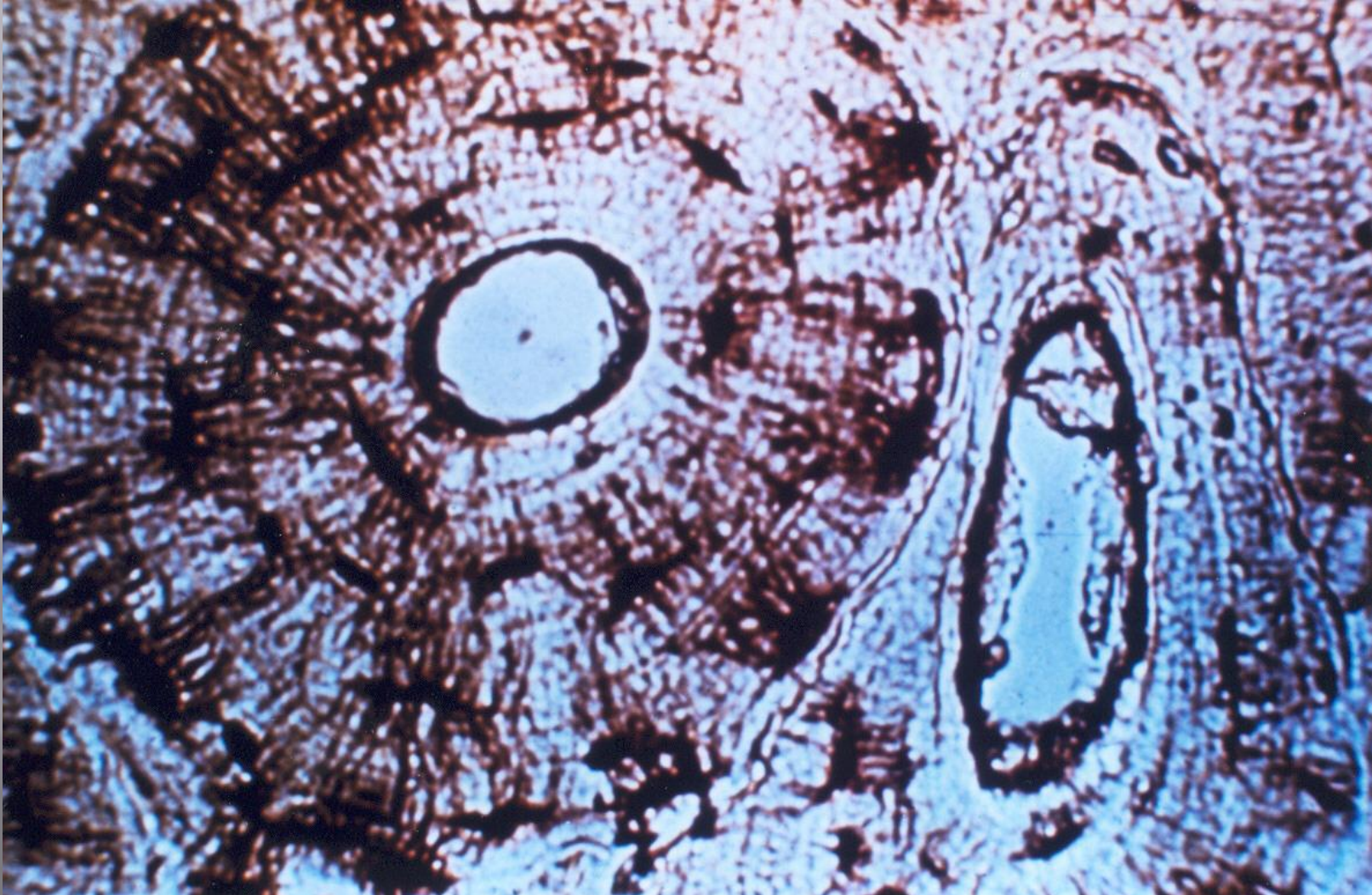Subadult Age:
Epiphyseal Fusion



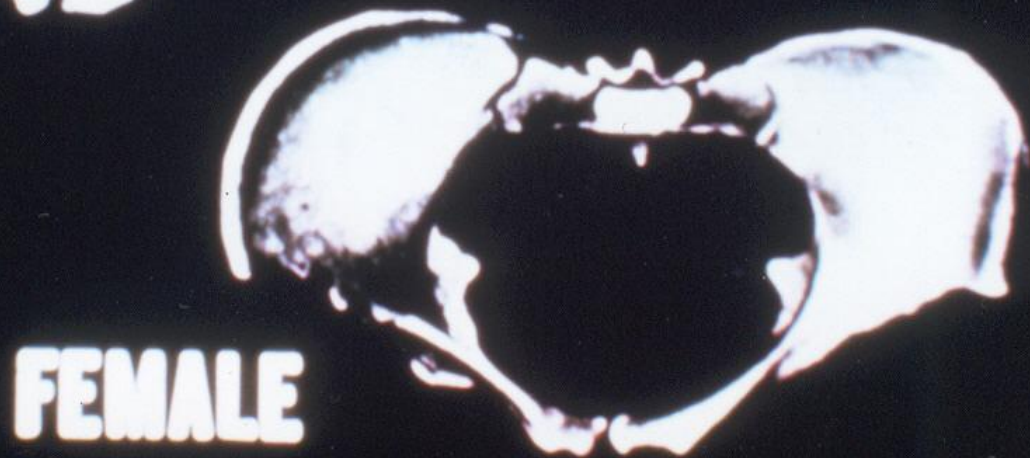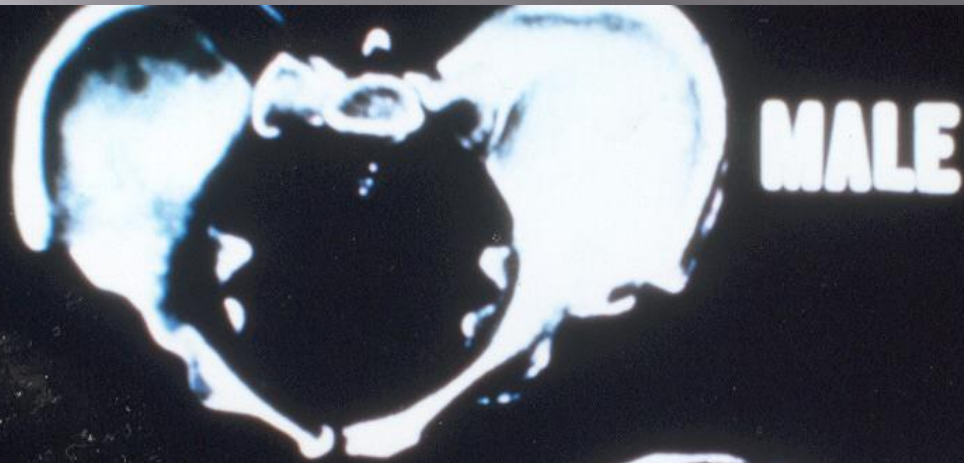
Adult Age: Pubic Symphyses



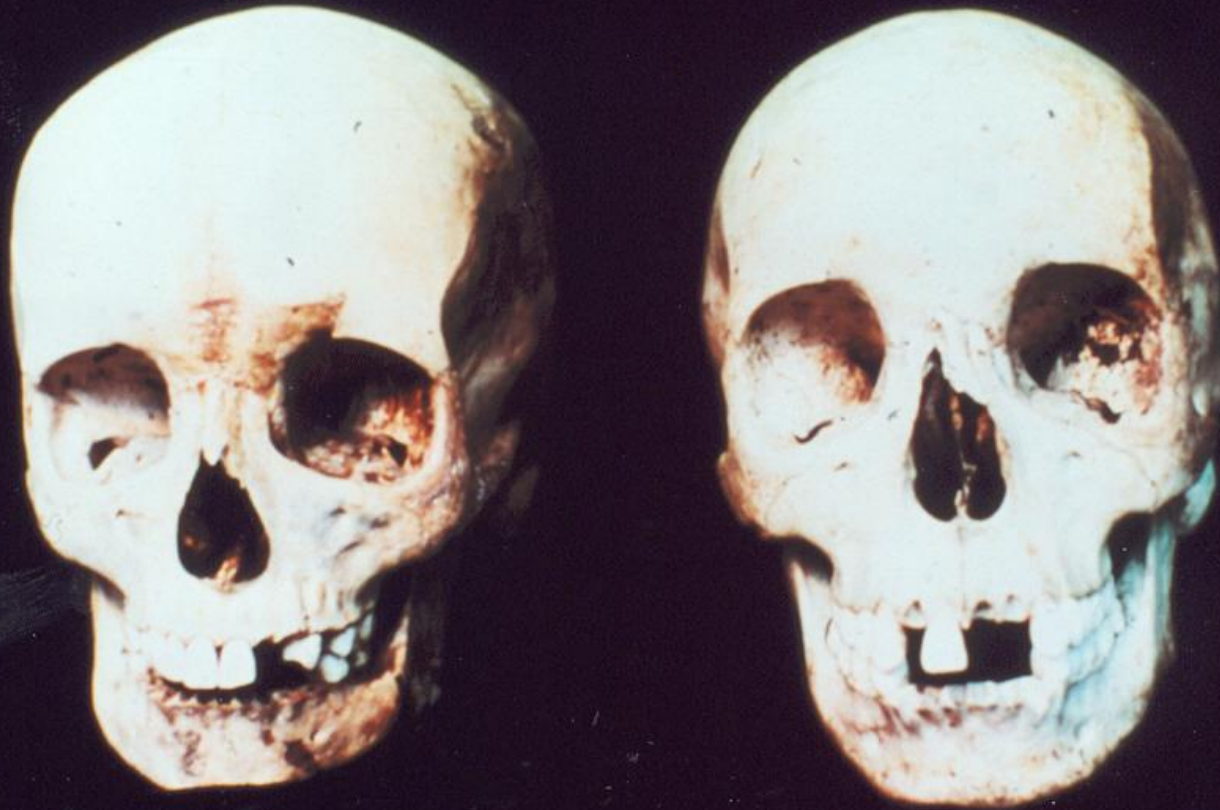Adult Age: Osteon Counting



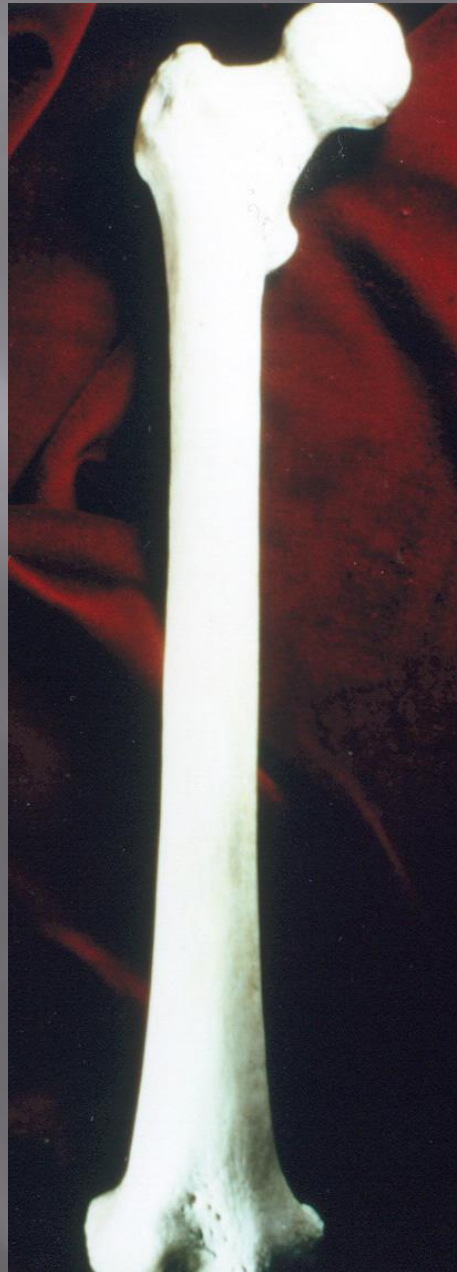
Determination of Sex



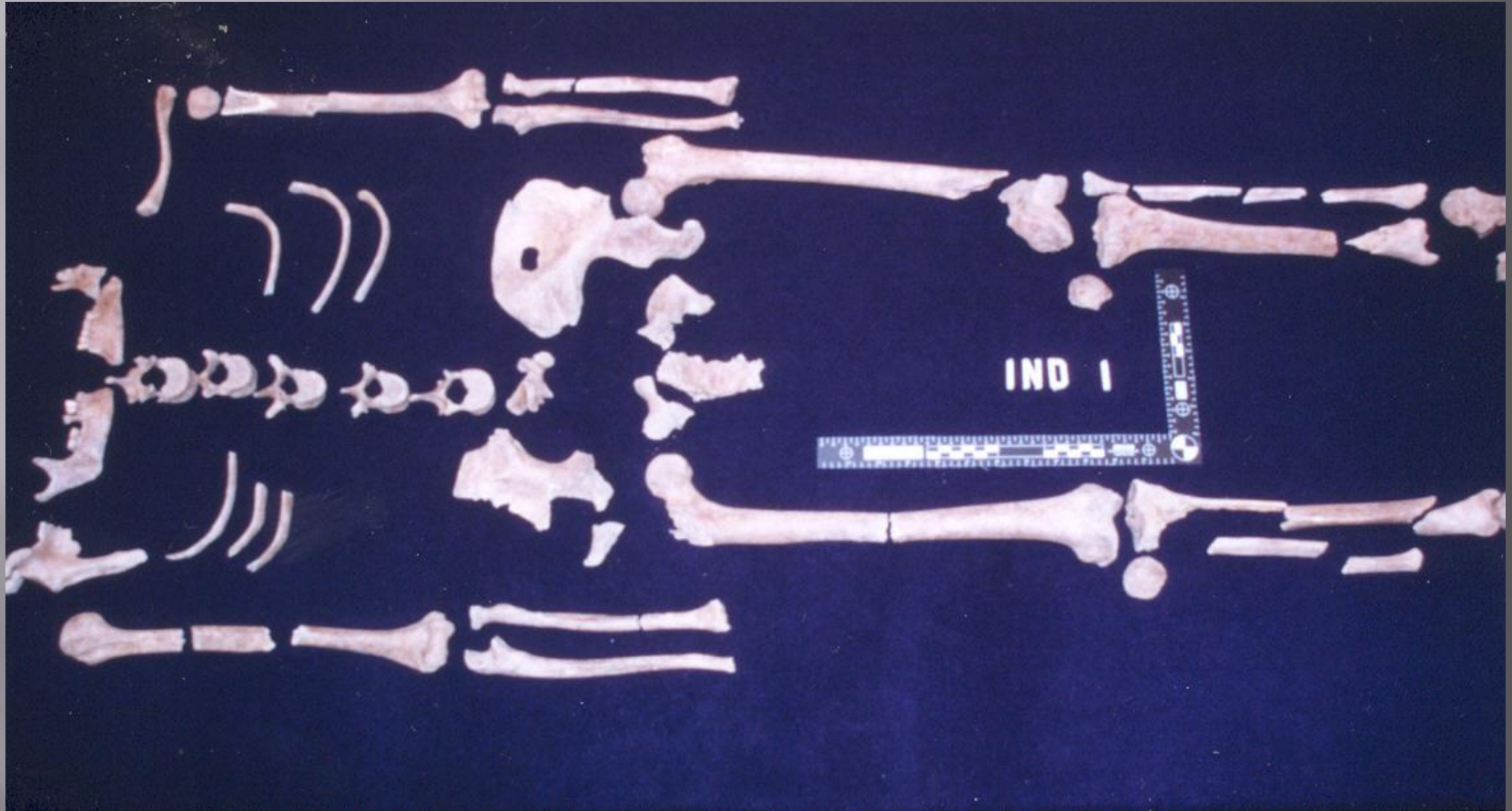
Determination of Sex, Ancestry



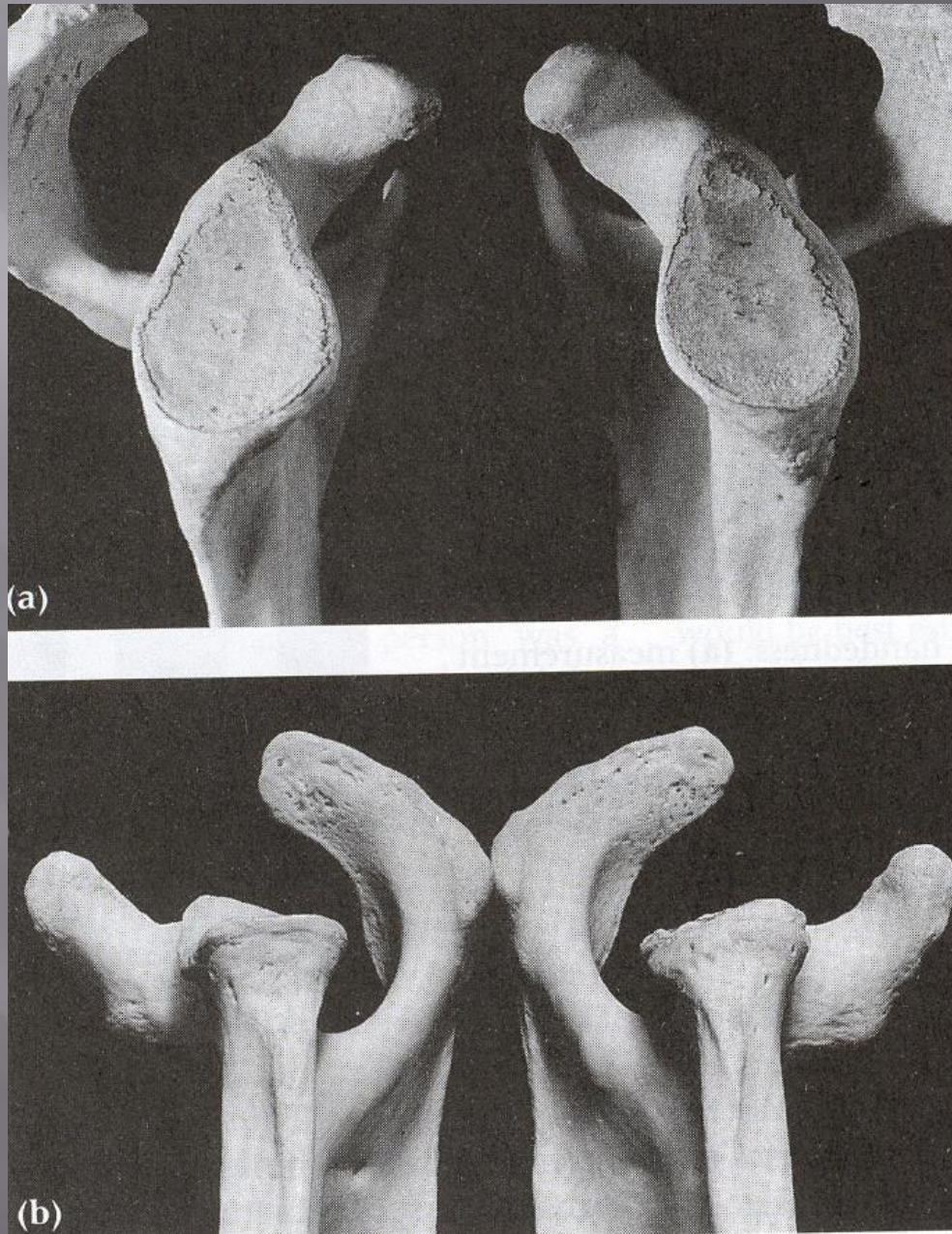
▣ Stature
determination



Body Weight



▣ Handed-
ness



Markers of Occupational Stress



Individuation

Requirements for Individuation

- ▣ A Suspected Identity
- ▣ Antemortem Records for the Suspected Identity, such as:
 - written documents
 - photographs
 - radiographs
 - memories of survivors

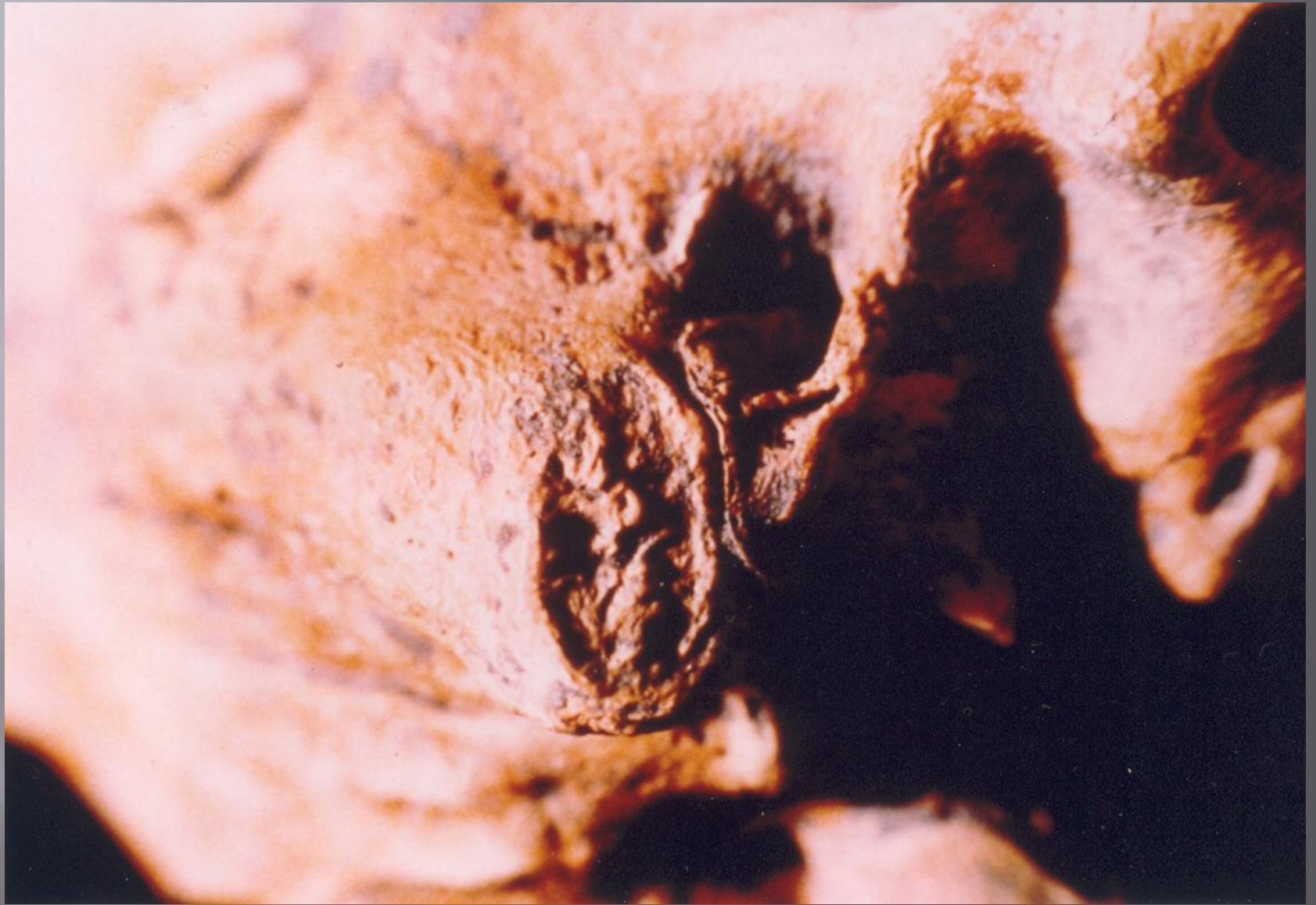Levels of Identification

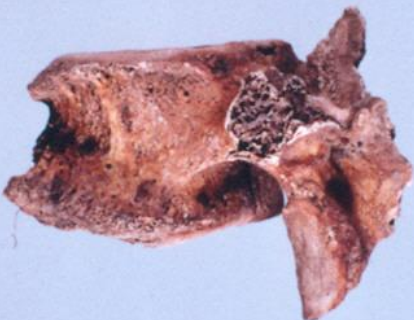- ▣ Tentative ID
- ▣ ID by Preponderance of Evidence
- ▣ ID by Exclusion
- ▣ Positive ID

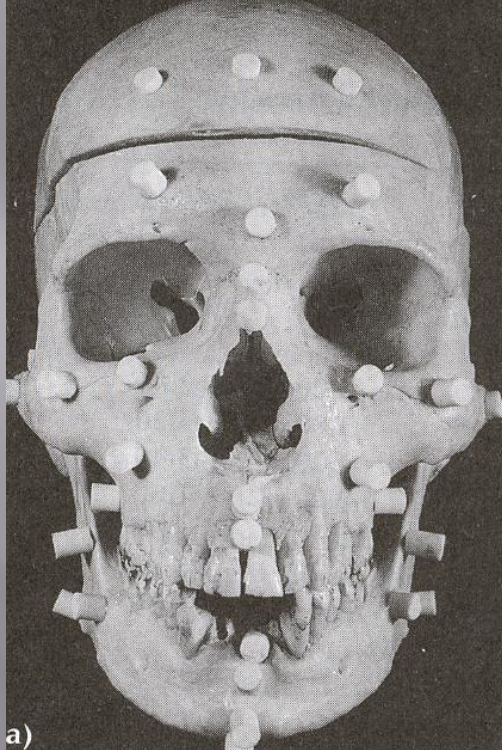
Tentative ID



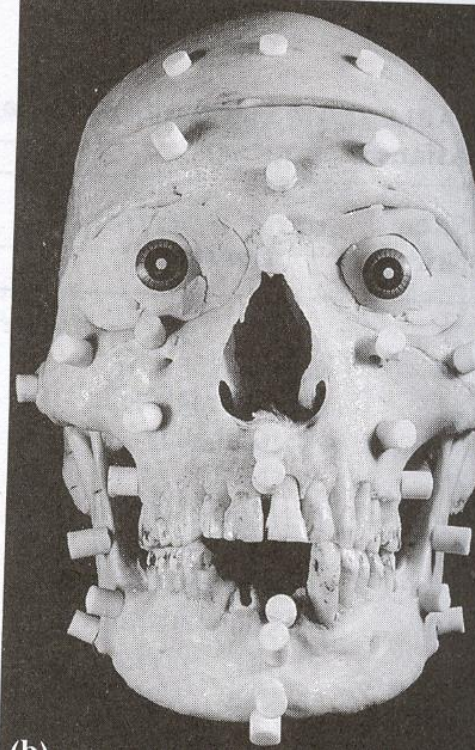ID by Preponderance of Evidence



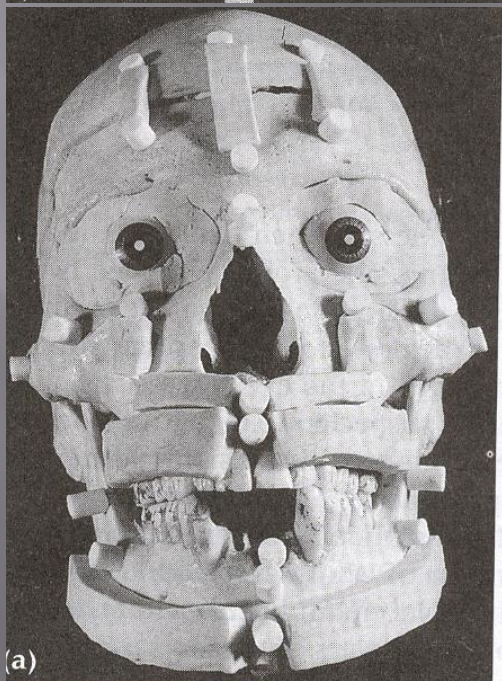




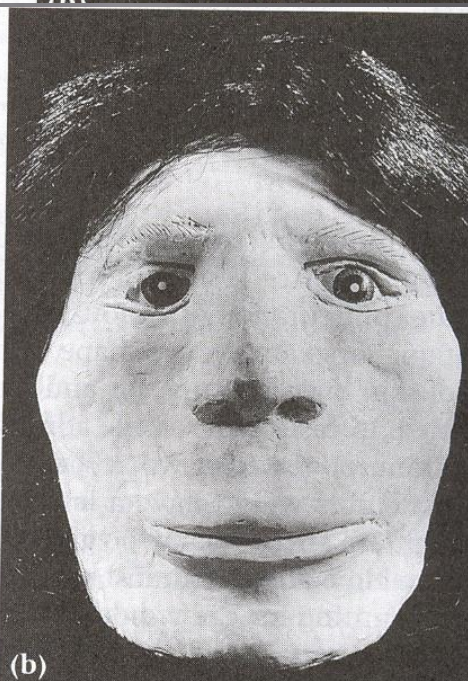
a)



b)



a)



b)

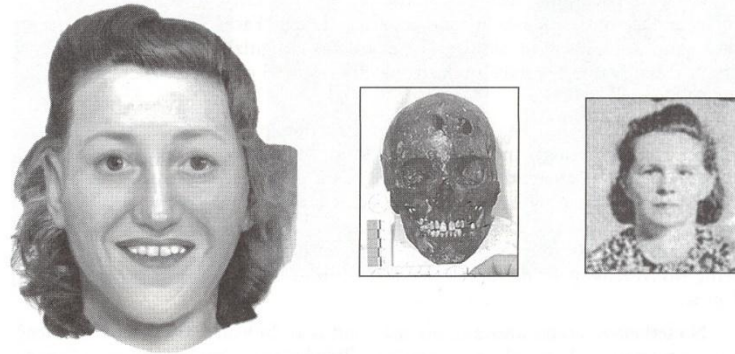

Fig. 7-3. A (above)—CARES reconstruction from skull of female next to actual photo, after identification was made; B (below)—CARES reconstruction from skull of unidentified female.

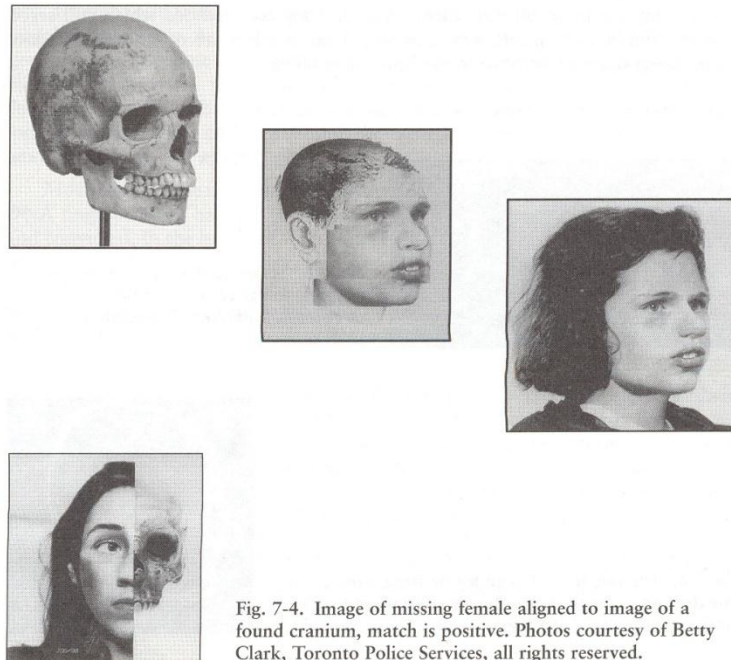


Fig. 7-4. Image of missing female aligned to image of a found cranium, match is positive. Photos courtesy of Betty Clark, Toronto Police Services, all rights reserved.

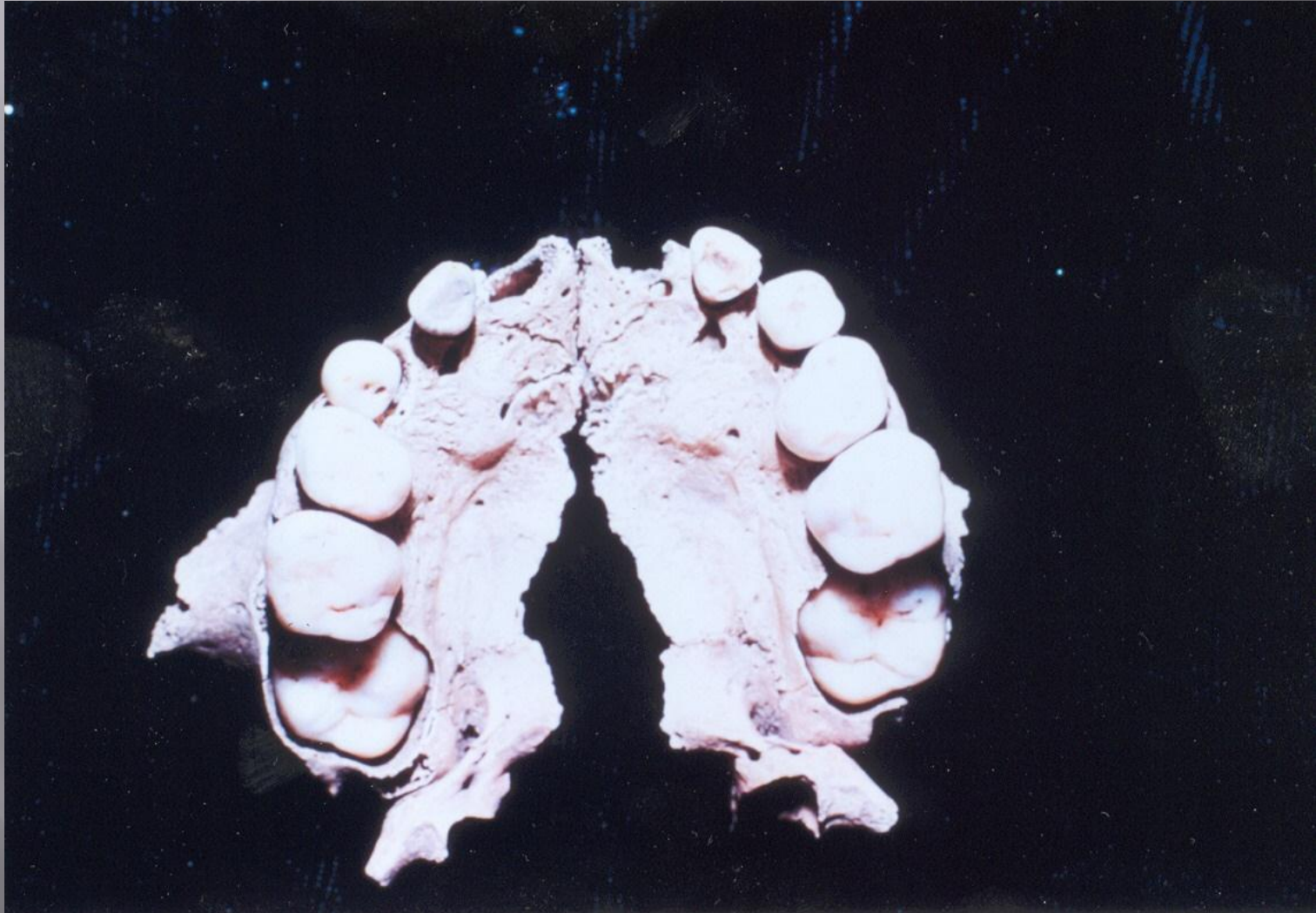
ID BY EXCLUSION

“Everybody else is accounted for”

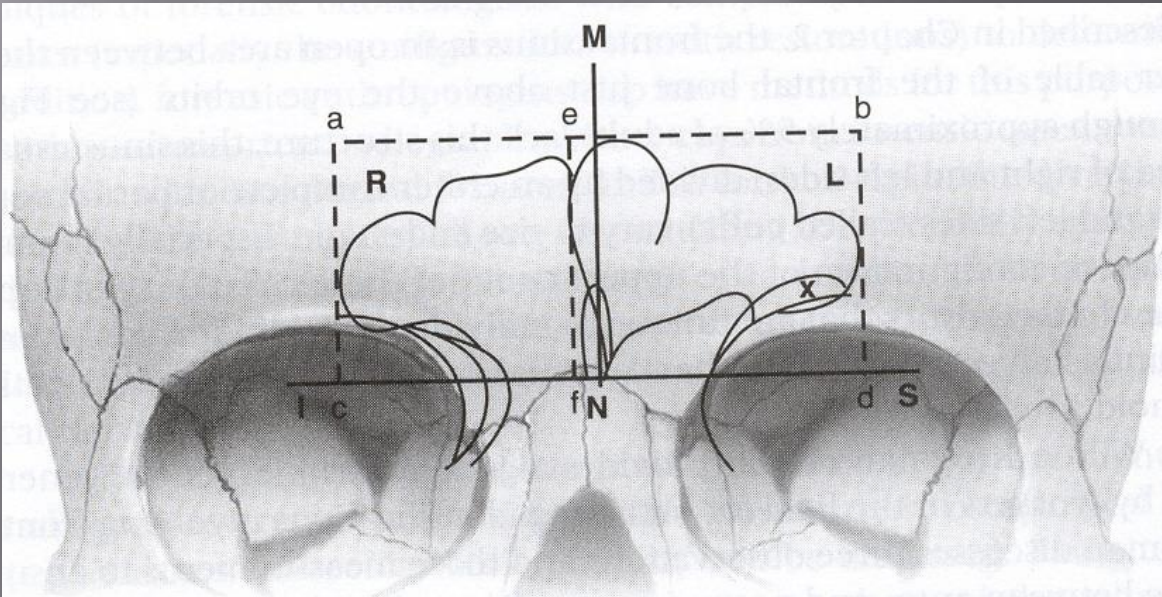
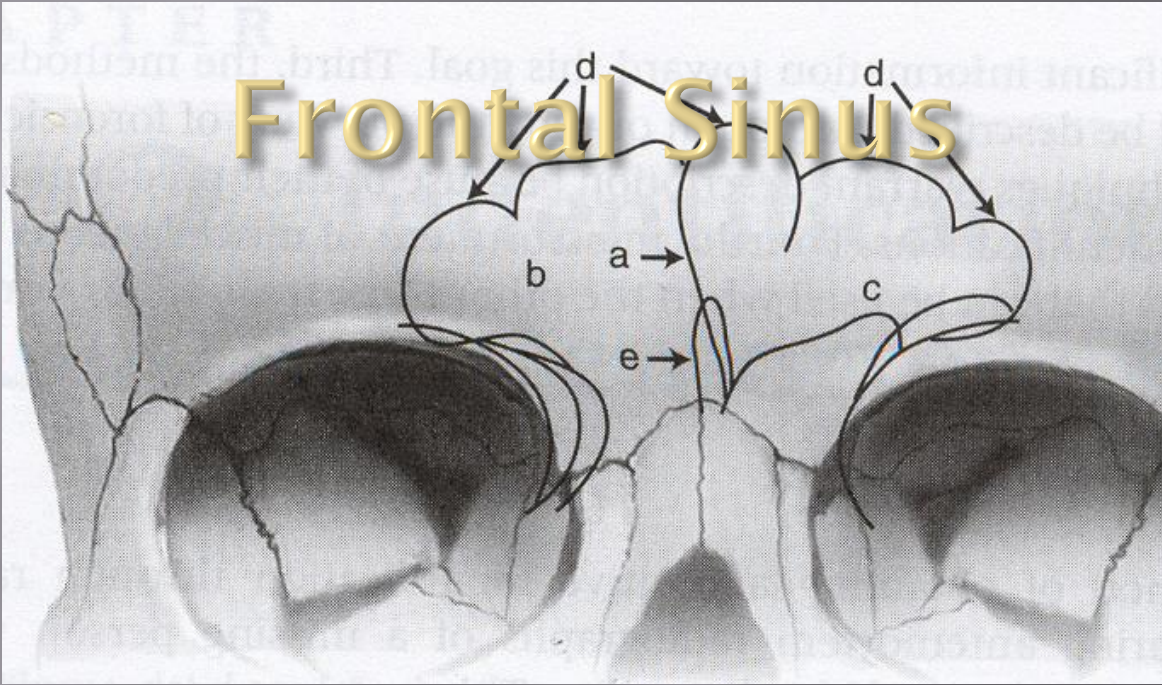


Positive ID

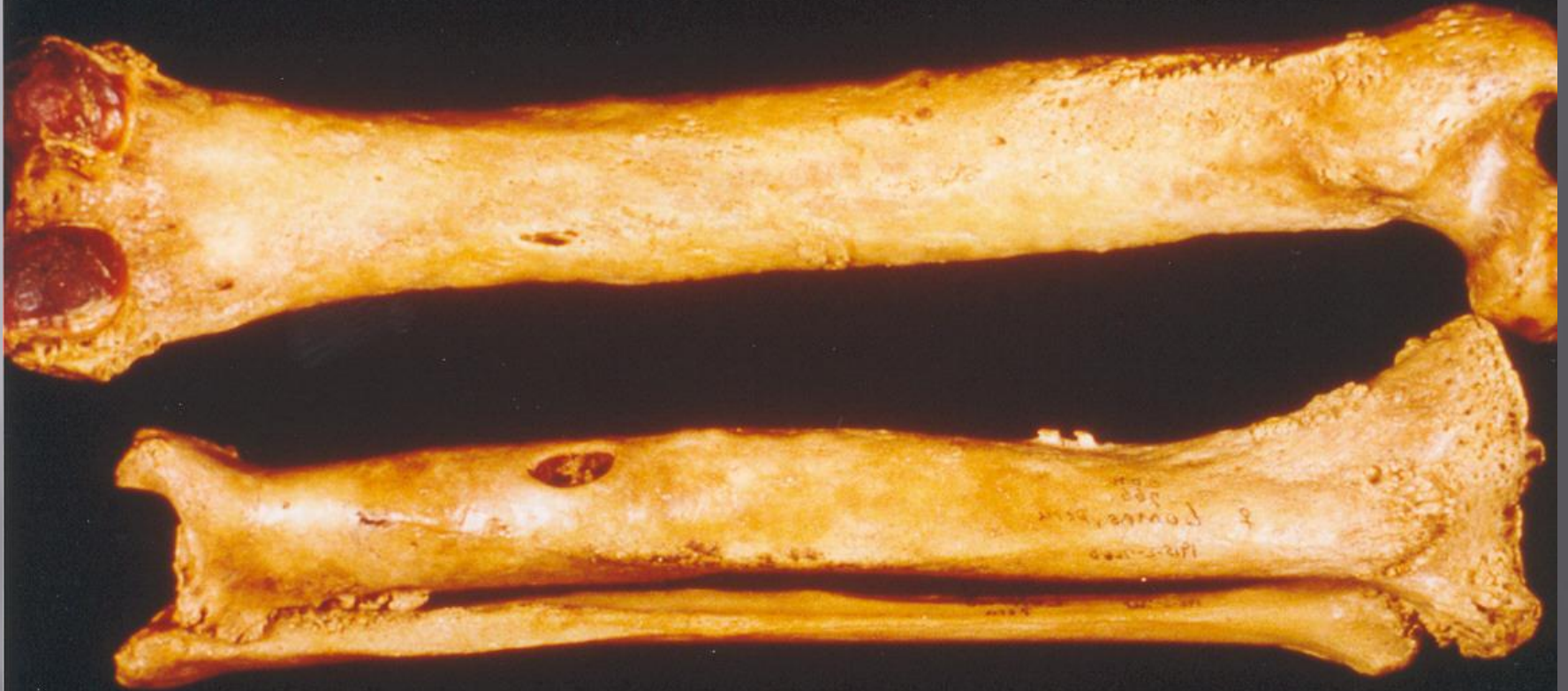Dental IDs

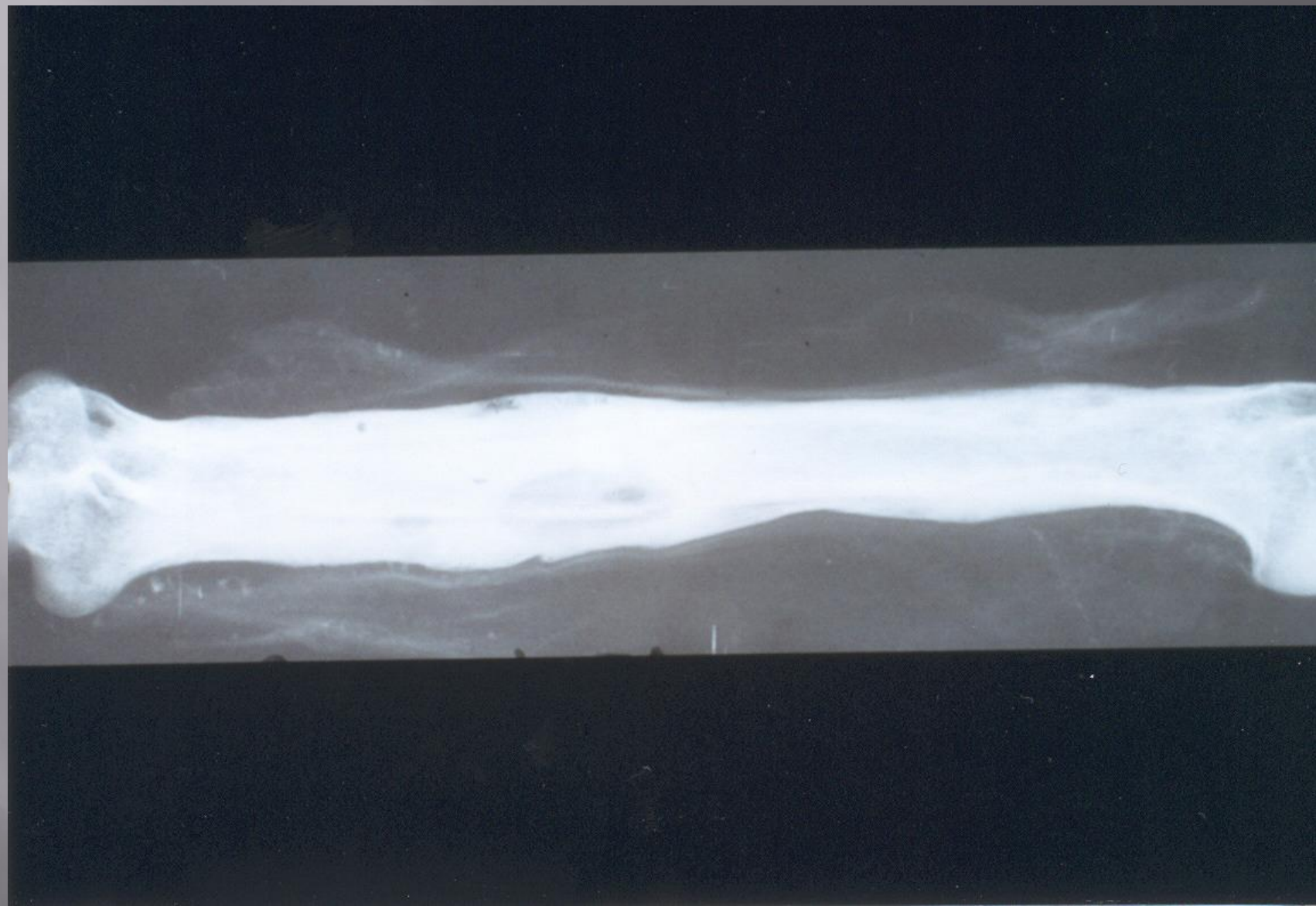


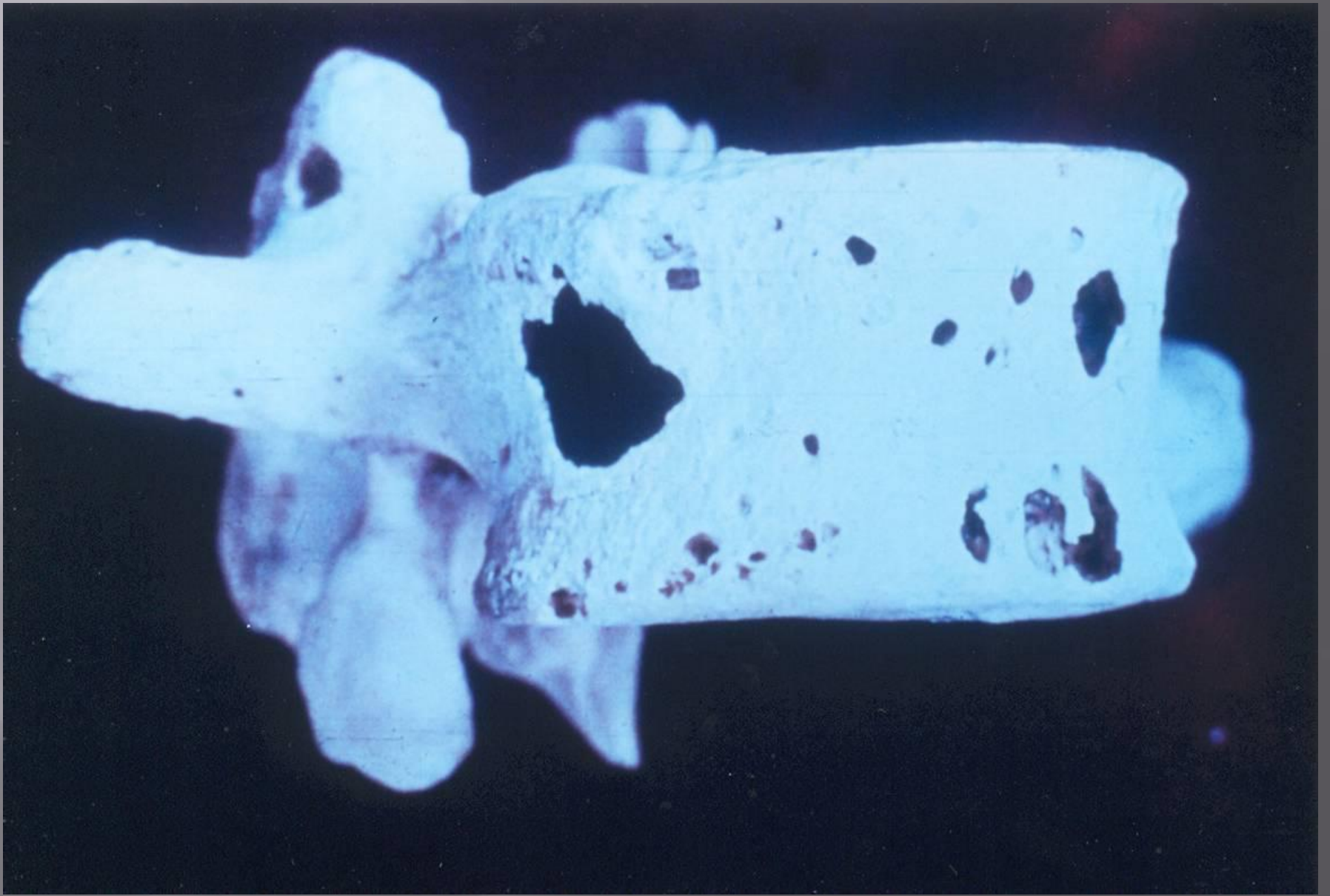
Frontal Sinus

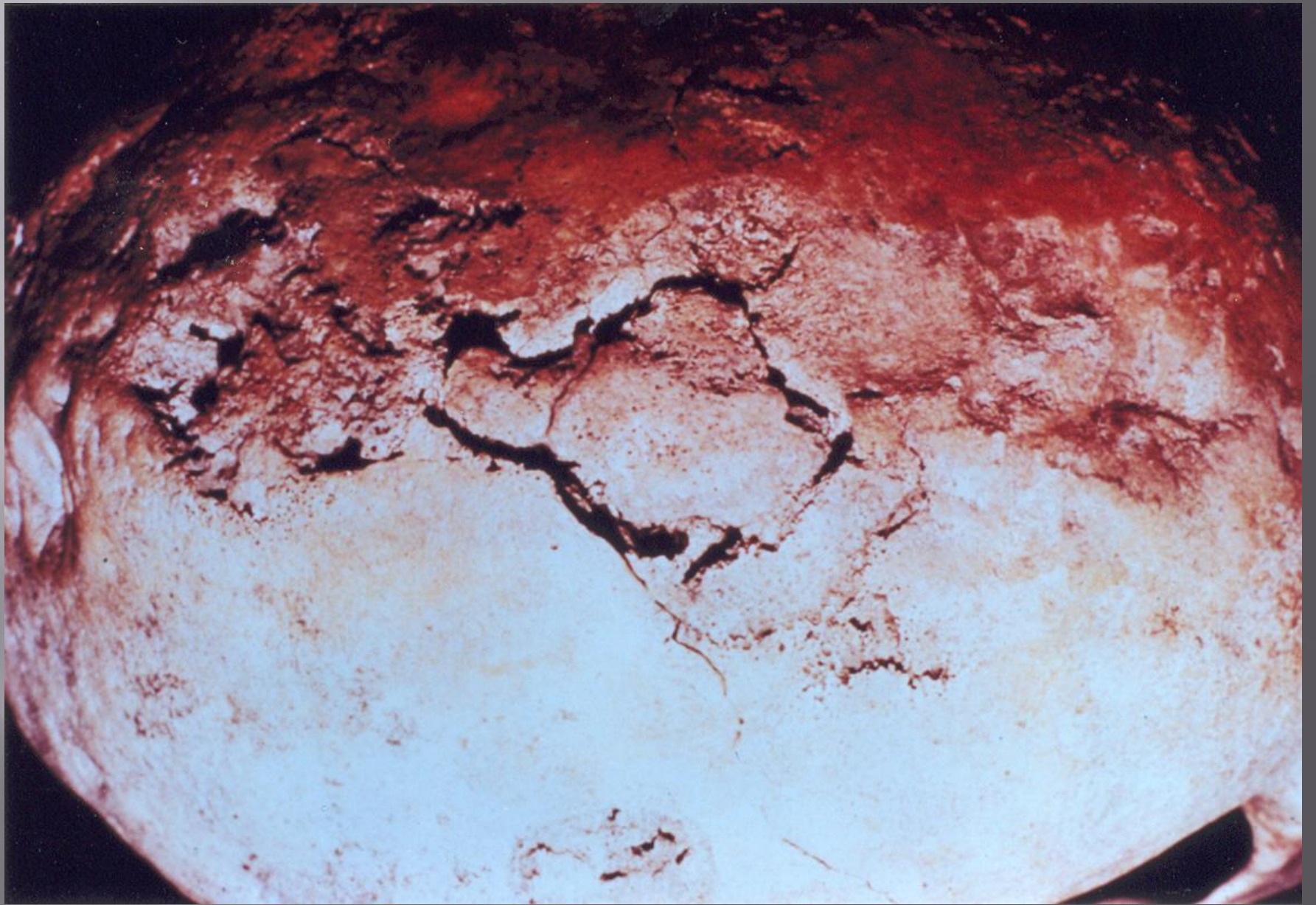


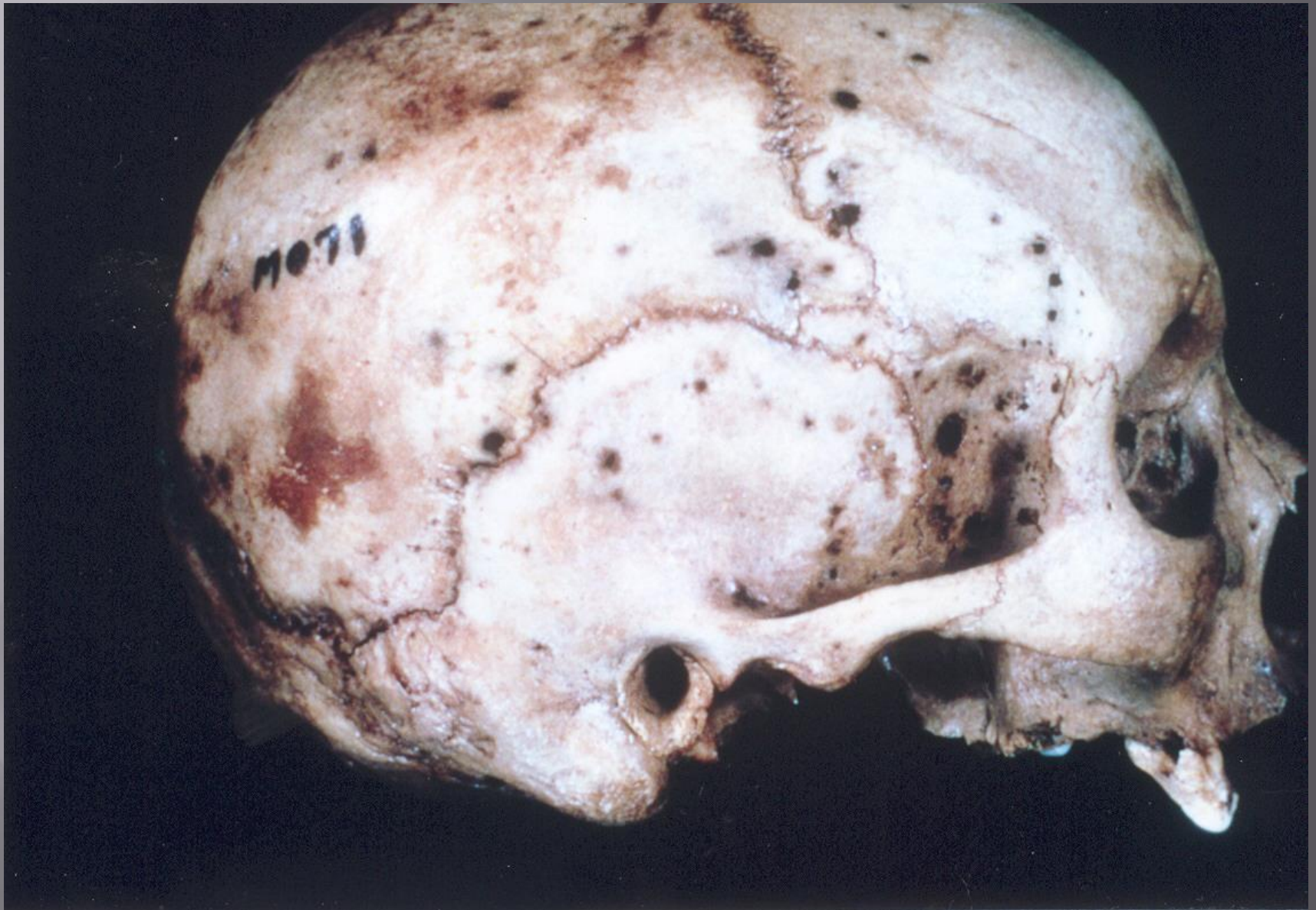Antemortem Pathologies

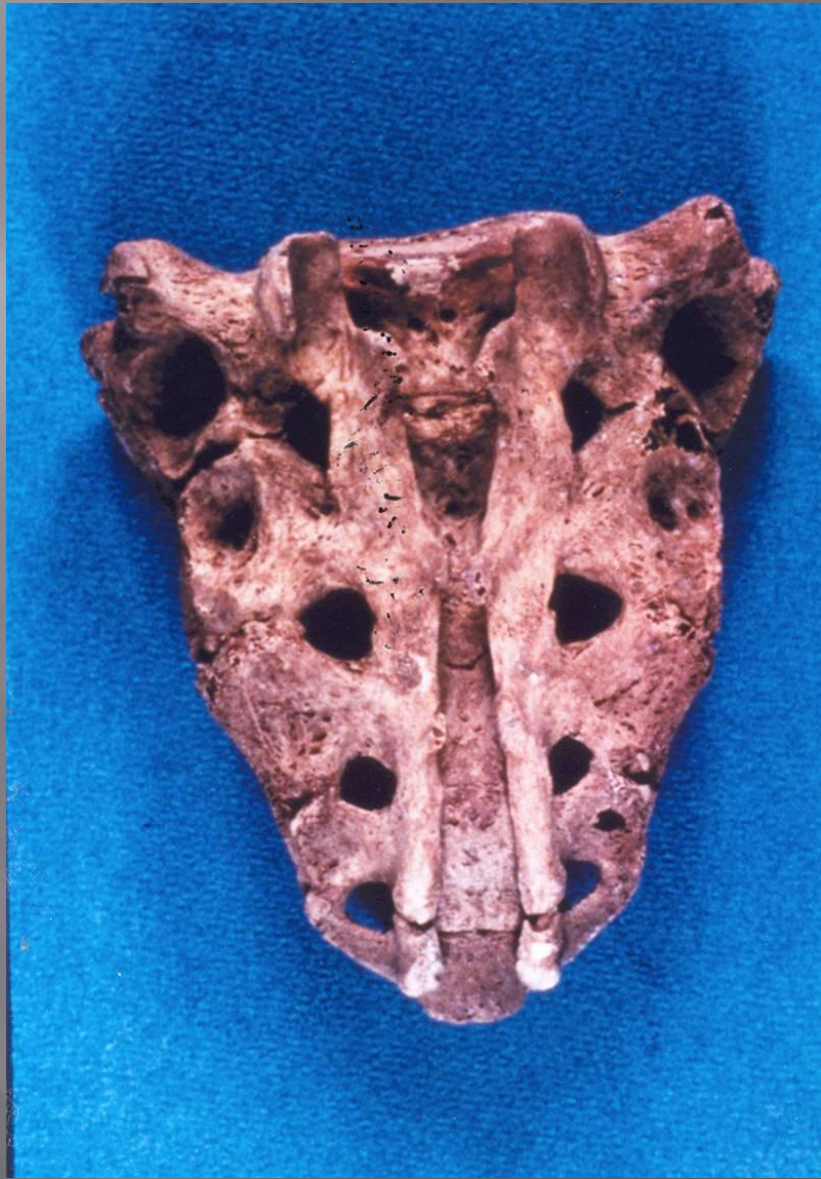

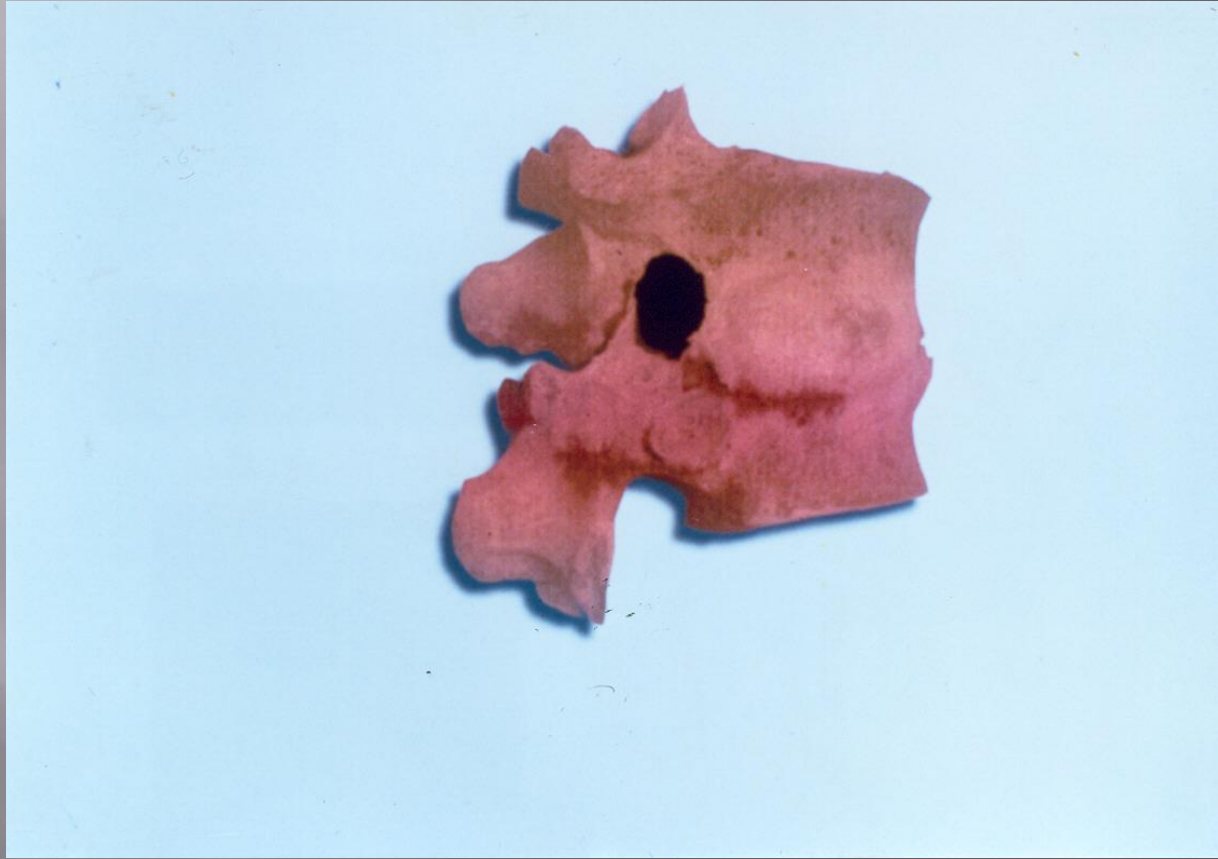





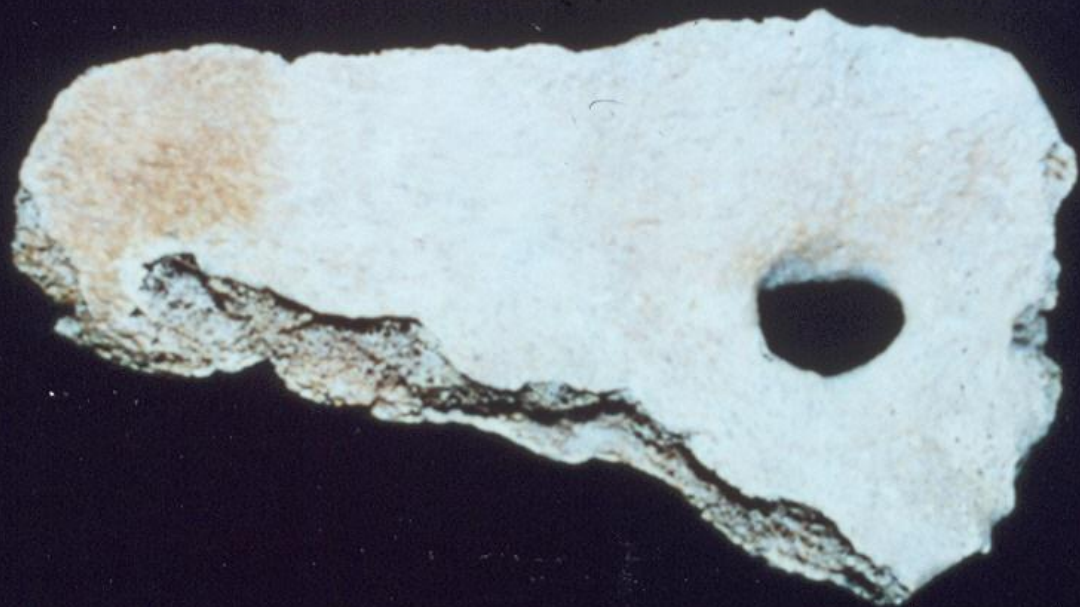


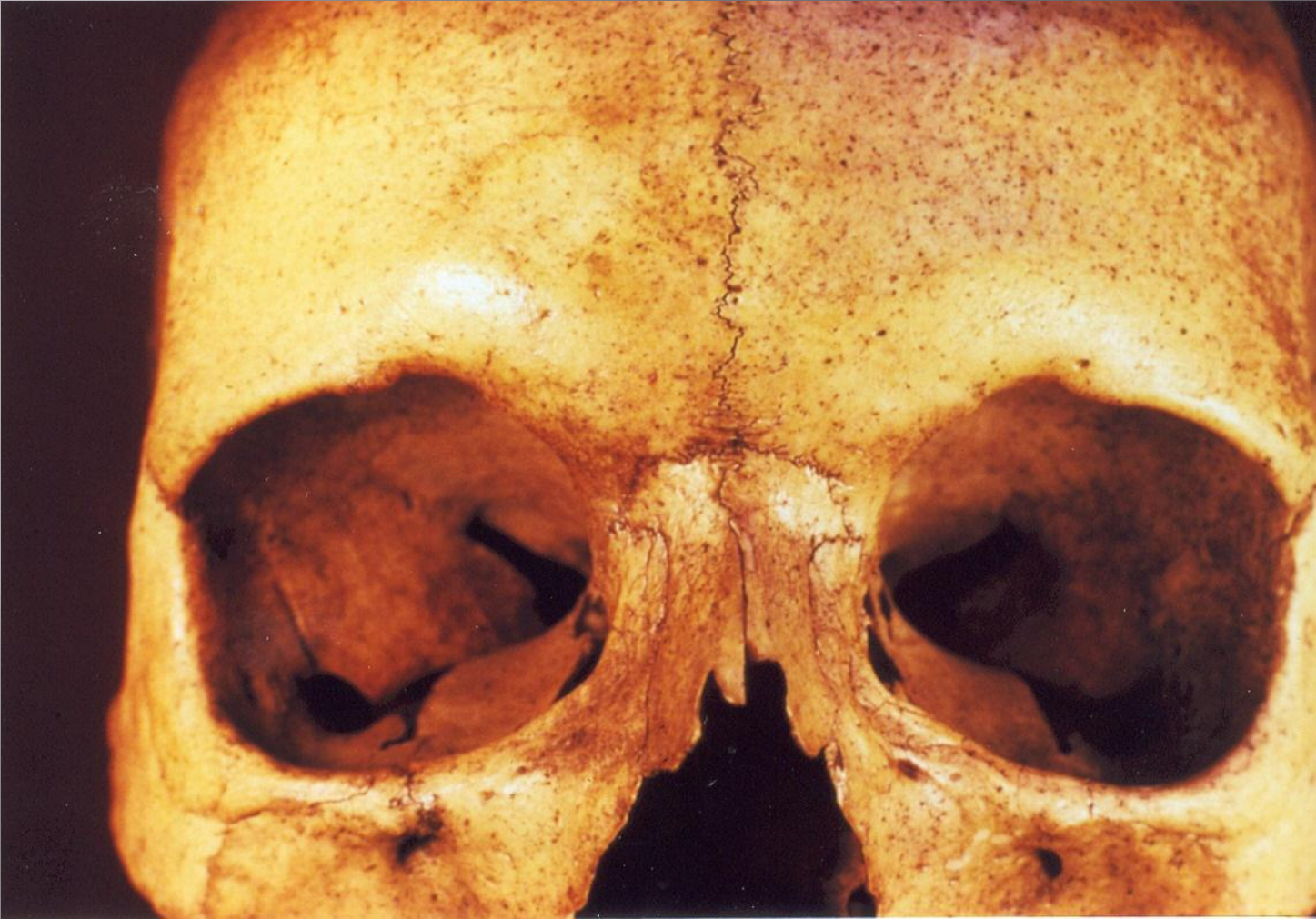


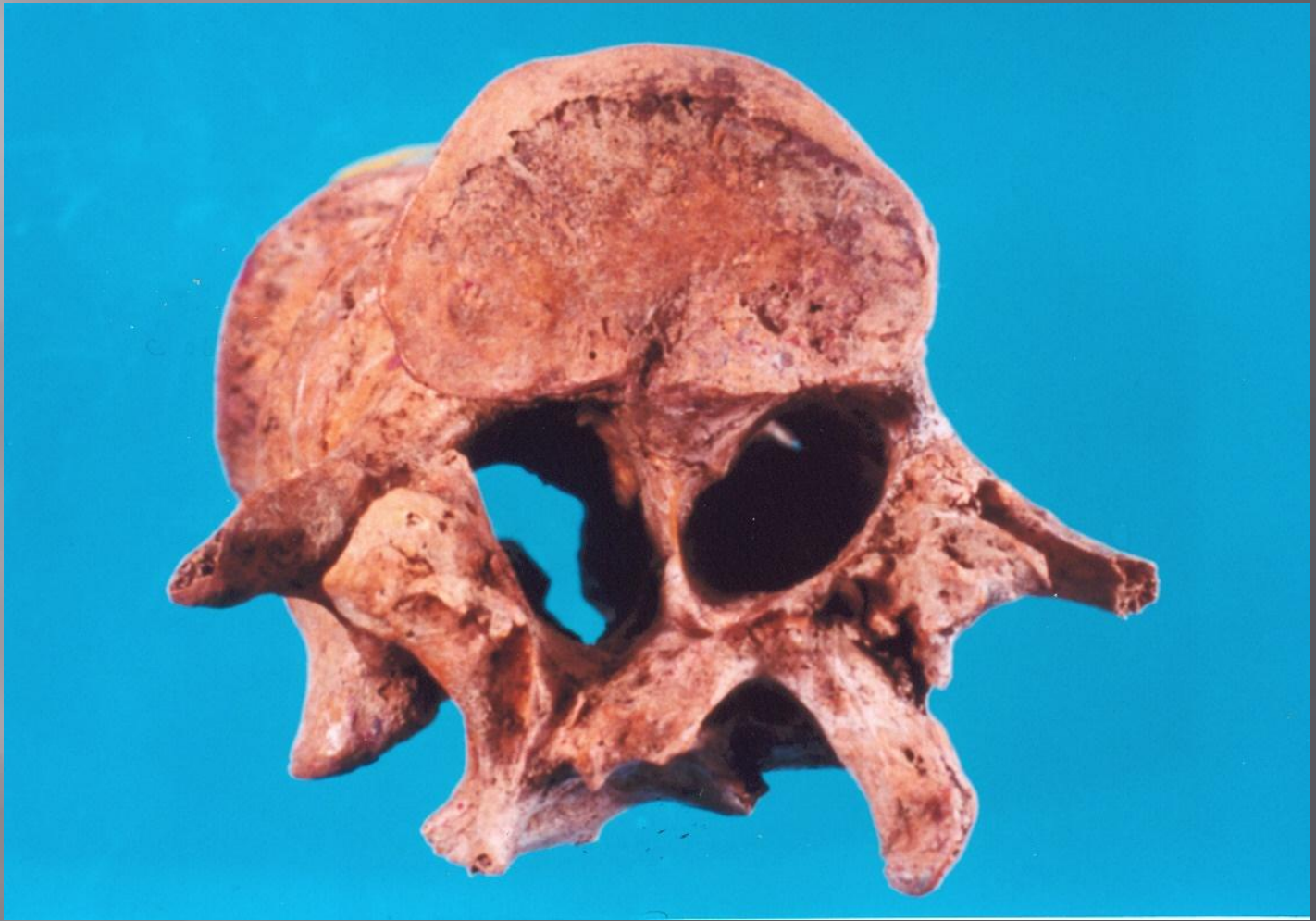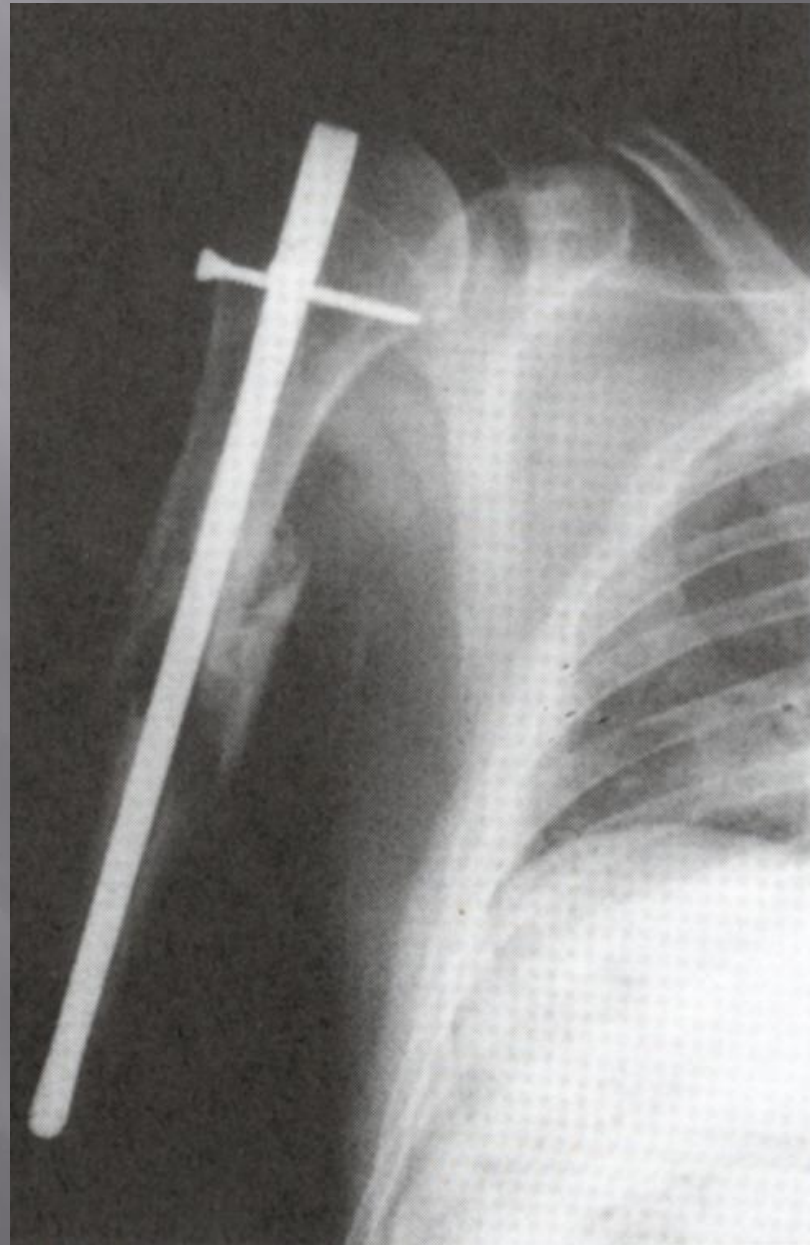




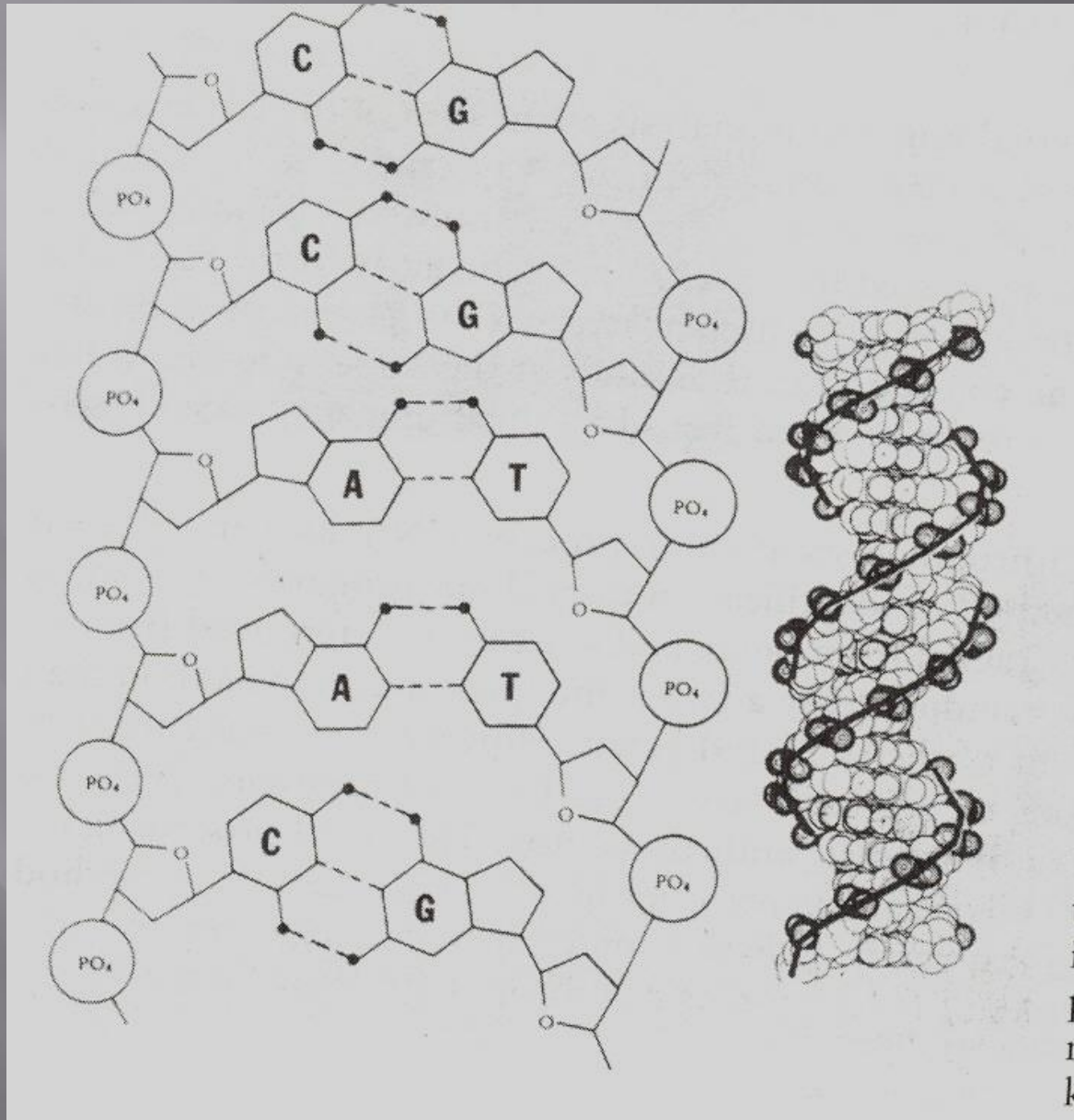








□ DNA



i
E
r
k

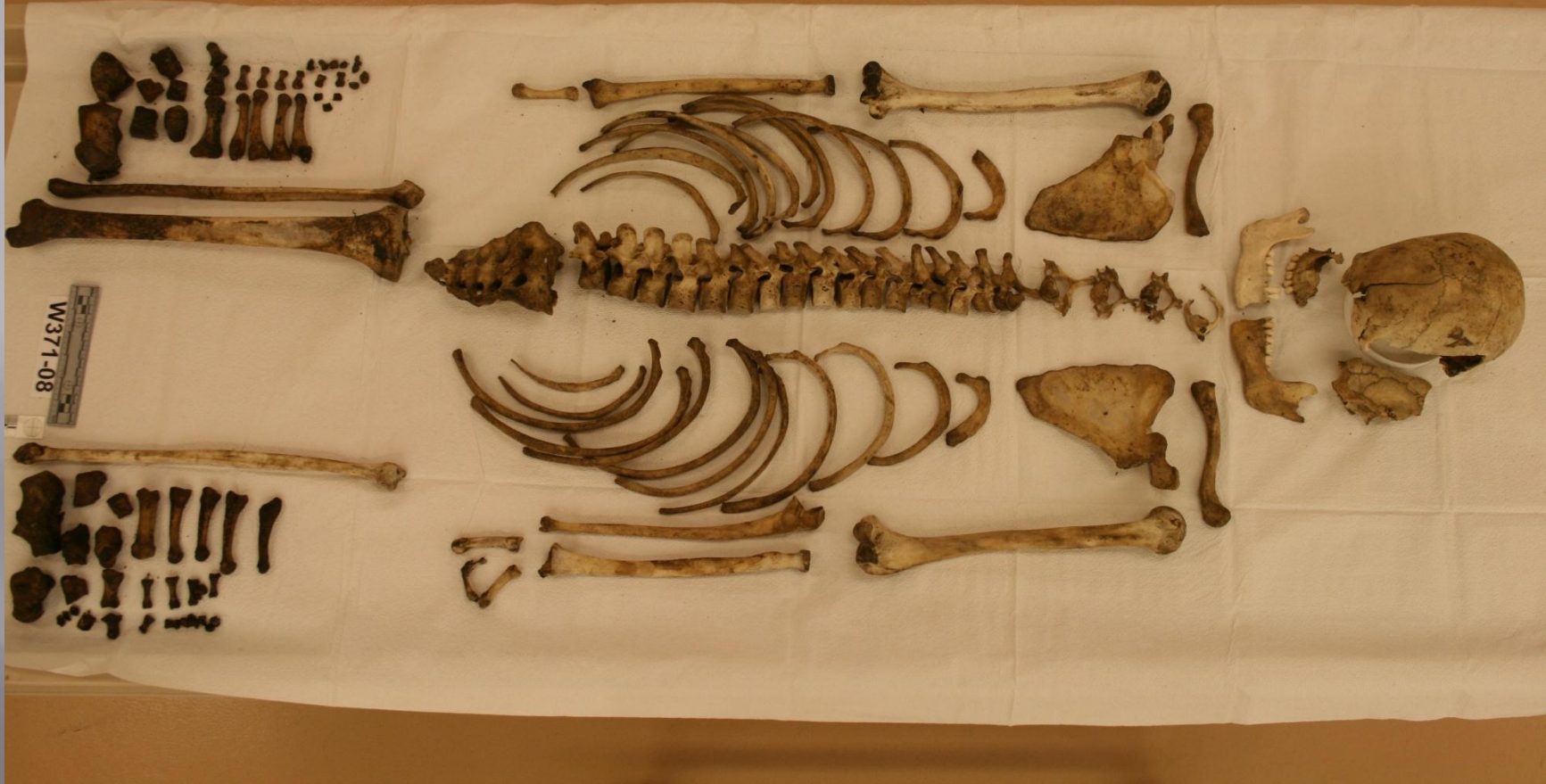CASE STUDIES



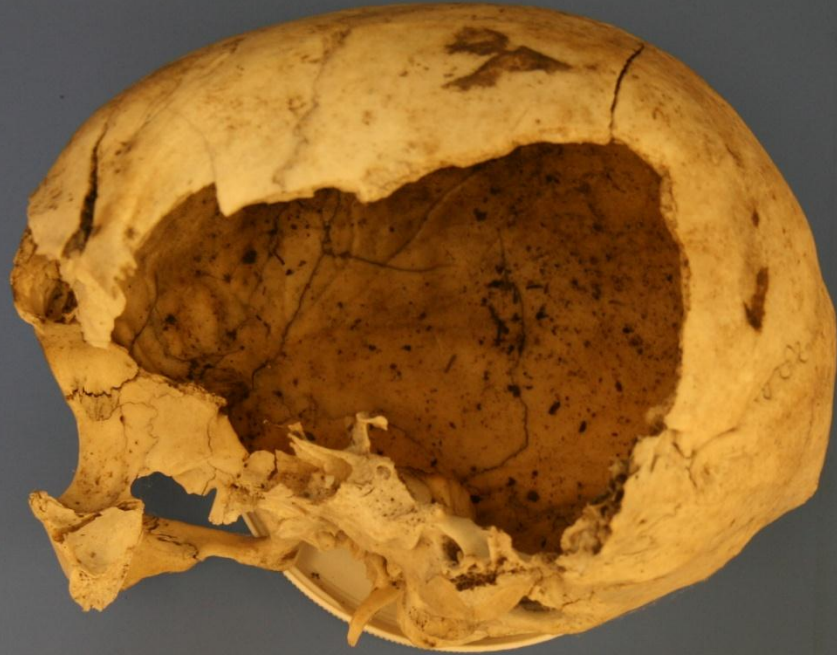




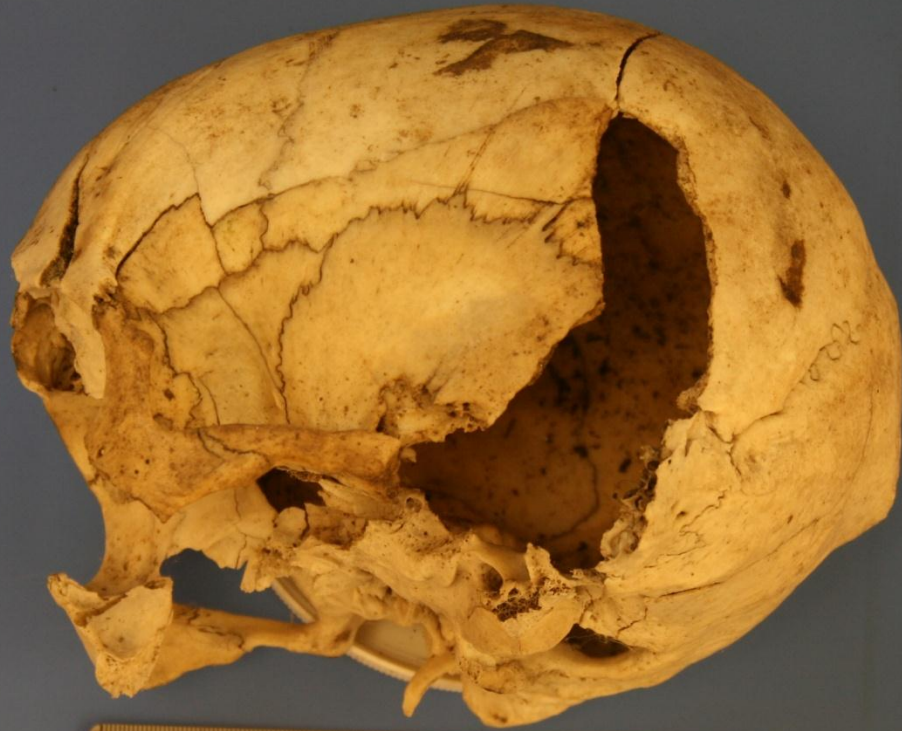




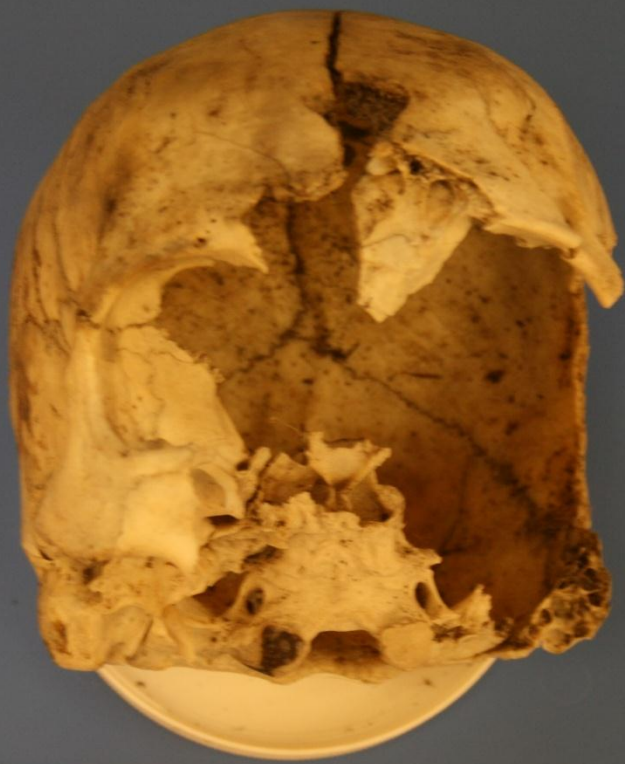W371-08



W371-08



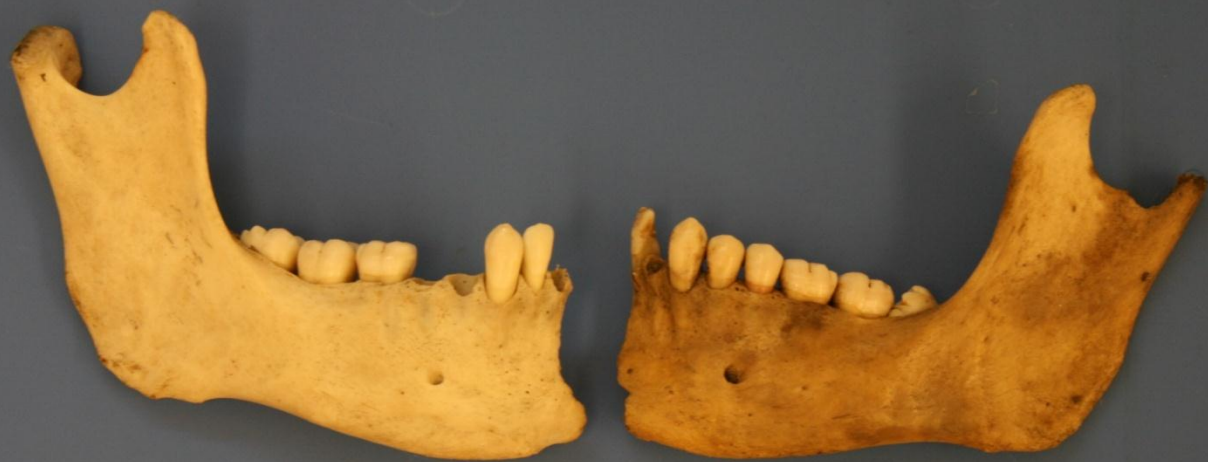
W371-08



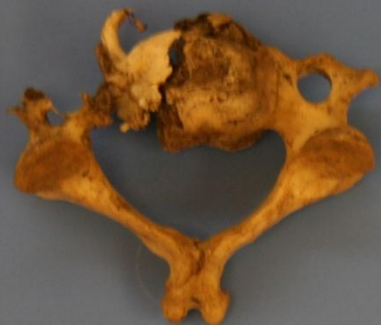
W371-08



W371-08



W371-08



W371-08